

Function, Injury, and Treatment for Meniscus

Jinyuan Cao ^{1,*†}, Beijie Chen ^{2,†}

¹ Brisbane Grammar School, Brisbane, Australia

² Mudu high school, Suzhou, China

* Corresponding Author Email: 2580692621@qq.com

†These Authors contributed equally.

Abstract. The meniscus is considered a vital structure for maintaining normal functions and perennial health of the knee joint. This study focuses on the meniscus and discusses its function, injuries and the corresponding treatments. Results show that two menisci are located in the knee joint- medial and lateral meniscus, which are different in shape but work together to provide specific functions. The main functions of the meniscus include load sharing, shock absorption, stability, joint lubrication and nutrition. Meniscal injuries include vertical longitudinal, radial, horizontal (cleavage), degenerative (complex), and bucket-handle tears, all of which can cause serious knee morbidity. There are different symptoms of meniscus damage, and the severity of the damage can be identified from the symptoms. Once the meniscus injury is found, conservative or surgical treatment should be carried out immediately. Conservative treatments generally include massage, acupuncture, and slight movement, as well as drug treatment. Surgical treatments include meniscus suture, partial meniscectomy, and meniscectomy. If it is not treated in time, the meniscus could cause irreversible damage and a series of sequelae.

Keywords: Meniscus, Anatomy, Function, Injury, Treatment

1. Introduction

The meniscus, the two crescent-shaped fibrocartilages located in a human's knee, was described as a residual structure in the 19th century [1]. However, with more studies into knee anatomy and biomechanism, the meniscus is now considered as an important structure for normal functioning and perennial health of the knee joint [2]. Subsequently, a meniscus injury may often have significant impacts on patients' knee function. Meniscal injury is one of the most common knee injuries with a mean annual incidence rate of 60-70 per 100000 while male hold predominance [3]. Different groups of people suffer different levels of meniscal injuries. For example, the male: female ratio ranges from 2.5:1 to 4:1 [4]. Since the high prevalence and vital impact on knee function, the protection of meniscus and treatments relevant to meniscal injuries are necessary to be studied and reviewed.

The primary role of the meniscus is to maintain the function of the knee through providing stability, distributing loads, providing lubrication and shock-absorbing [5]. Current studies and research regarding meniscus are mainly focused on meniscal injuries and relevant treatments. Meniscal injuries are considered to be a source of serious musculoskeletal morbidity [6]. Due to the complex anatomical and biomechanical traits of the meniscus, they are prone to injury and damage. In terms of treatments, surgeries are popular treatment options.

Although a great number of remarkable studies into specific meniscal injuries and treatments have been done and published, it is seen that there is a lack of reports summarising all relevant pieces of information. Thus, this article comprehensively discusses the human meniscus from aspects of anatomy, function, injury, and treatment.

2. Background of Meniscus

2.1. Gross Anatomy

Studies of meniscal anatomy have extensively developed since the meniscus was described as ‘the functionless remnants of intra-articular leg muscles’ in 1897 [1]. It is important to understand meniscus anatomy and its relationship with types of meniscal injuries and treatments.

The word ‘meniscus’ is originally from Greek word ‘meniskos’ which means ‘crescent’ or a ‘small moon’. The menisci are two crescent-shaped or semi-circular fibrocartilaginous wedges located between the femoral condyles and tibial plateaux. There are two pieces of the meniscus, one located on the medial aspect of the knee joint and the other one located on the lateral aspect (Figure 1). Both menisci have a concave superior aspect, allowing strong articulation with the convex femoral condyles. Meanwhile, the inferior portions of menisci are relatively flat to comply with the tibial plateau (Figure 2). The circumference of both menisci is attached tibial plateau via the coronary ligaments [5].

2.1.1. Medial Meniscus

The medial meniscus is crescent-shaped. The width of its posterior horn is greatly larger than its anterior horn’s (Figure 1). Also, the anteroposterior proportion is larger than the mediolateral proportion. The anterior horn is strongly connected to the anterior cruciate ligament (ACL). The posterior horn is attached adjacent to the posterior cruciate ligament (PCL). The medial meniscus attaches to the upper surface of the tibia via the coronary ligament [6].

2.1.2. Lateral Meniscus

The lateral meniscus is invariantly disk-shaped. Further, it is smaller in size but more mobile than the medial meniscus. Its anterior horn is attached to the intercondylar fossa while the posterior horn is attached to the PCL through the ligament of Wrisberg [7].

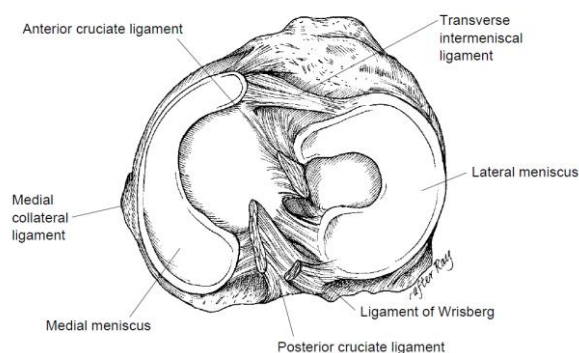


Figure 1 Anatomy of the meniscus [8]

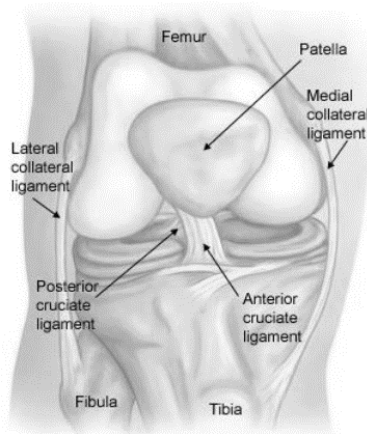


Figure 2 Front view of the knee joint

2.2. Biomechanics and Functions

The major meniscal functions are load distribution, shock absorption, stability, nutrition and joint lubrication. If the meniscus is removed, the knee joint line would become narrow, ridge, and square. It shows the importance of meniscus in joint protection and led to more investigations into meniscal functions [5].

2.2.1. Load Sharing

Peripheral meniscal stress measurements have shown that healthy menisci transmit 45% to 70% of weight-bearing load. Biomechanical studies have suggested that both menisci transmit approximately 40%-60% of load acting on an extended knee joint, within which the lateral meniscus distributes 65-70% and medial meniscus distributes 40-50%. This increases to 90% in a knee flexion [5,8].

2.2.2. Shock Absorption

Studies measuring bovine menisci have shown that meniscal tissue is 50% less rigid than articular cartilage. Also, Voloshin and Wosk suggested that the shock absorption capacity of a normal knee is approximately 20% less after removal of meniscus from meniscectomy [9].

2.2.3. Stability

The meniscus is also a vital structure in improving joint stability. The concave superior portions of each meniscus help fix the discordant articulation between the convex femoral condyles and the flat tibial plateau [8]. The medial meniscus is firmly attached to the tibia, enhancing the anterior stability of the knee. Studies have suggested that removal of medial meniscus through meniscectomy has a minor effect on the anteroposterior motion for knees with intact ACL. However, the ACL-deficient knee experiences an increased anterior tibial translation of up to 58% when bending at 90 degrees [10].

In an ACL-deficient knee, the posterior horn of medial meniscus plays the most important role in withstanding anterior tibial force. A recent study has suggested that lateral meniscus is important for pivot-shift maneuver as it was observed that lateral meniscectomy contributes to increased translation, rotation, and the pivot shift [11].

2.2.4. Joint Lubrication and Nutrition

The meniscus contributes to knee joint lubrication and nutrition. MacConaill reported meniscectomy resulted in an approximately 20% increased friction coefficient in the knee joint [12]. Many authors believe that when meniscus is compressed by load, it releases synovial fluid into the articular cartilage, lubricating and nourishing the knee joint.

3. Meniscus Injury

3.1. Epidemiology

Meniscal injury is one of the common types of knee injuries that are frequently seen by orthopedic surgeons. The mean annual incidence of a meniscus tear is 60-70 per 100000, with males holding predominance. The overall male-to-female ratio is ranged from 2.5:1 to 4:1 [3]. Poehling et al reported that over one-third of meniscus tears are associated with an ACL injury [13]. Males aged 21-30 years and females aged 11 to 20 years hold peak incidence rates. Degenerative tears are often found in men aged 40-69 years [5].

Meniscal tears are commonly caused by a shear load on the meniscus generated by an amalgamation of axial loading and rotational force [14]. Traumatic tears are frequently caused by a known source of damage to the knee and can be independent or associated with ligamentous injuries or injuries to the articular surface. Younger active patients are prone to experience an acute traumatic injury. Degenerative tears may be caused by long-term stress cumulation and be associated with chondromalacia [14].

Symptoms of meniscal tears include commonly pain and sometimes moderate swelling. It is less common to see ‘mechanical’ symptoms like locking knee and grinding knee.

3.2. Types of Tears

There is no universally accepted classification of meniscal tears. However, tears are normally classified based on the tears pattern or the thickness of the tears. The main types of meniscus tears are summarised below which are vertical longitudinal tear, bucket-handle tear, transverse or radial tear, horizontal or cleavage tear, and degenerative or complex tear.

3.2.1. Vertical Longitudinal Tears

A vertical longitudinal tear is perpendicular to the tibia plateau. This tear damages the circumferential collagen fibers transversely (Figure 3), causing either complete separation of the meniscus or only a single portion is broken. Vertical longitudinal tears are the most common type of traumatic tears with males of 21-30 years of age and females of 11-20 experiencing peak incidences. It is observed that medial cases more frequently occur individually while lateral cases more frequently occur in association with ACL tears [5].

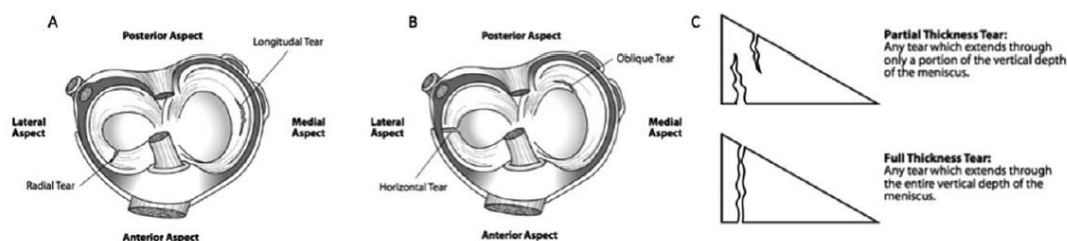


Figure 3 Common patterns of meniscal tears (A and B) and; (C) depth of tears [15]

3.2.2. Radial Tears

Radial tears are vertical tears with an incidence rate of approximately 14-15%. It normally occurs between the posterior horn and middle thirds. Also, it normally extends from the inner rim toward the circumference. Radial tears occur more frequently among young patients. Radial tears are more likely to be seen in younger patients, with a peak incidence rate among males aged 11-20 years and females aged 51-70. Radial tears majorly (approximately 79%) occur in the posterior horn [16-18].

3.2.3. Horizontal Tears

Horizontal tears are presented in the lateral-medial direction which separates the injured meniscus into inferior and superior parts. This type of tears occurs more often in the posterior portion of the medial meniscus. It's often influenced and related to lateral meniscal cysts or osteoarthritis if found in the lateral meniscus [8].

3.2.4. Degenerative or Complex Tears

Degenerative or complex tears are tears that appear two or more configurations or are difficult to be categorised into one specific type [19]. This type of injury is the most common among all meniscal injuries (30%). The peak incidence for male happens between 41-50 years of age while 61-70 years of age for female [20]. Complex degenerative tears are often found in association with other degenerative knee damages.

3.2.5. Bucket-handle Tears

A bucket-handle tear is a vertical or oblique tear commonly extending from the posterior horn to anterior horn. The name of bucket-handle tears is originated from the tear pattern, in which the inner fragment often displaces toward the intercondylar notch to form a ‘bucket-handle’. Bucket-handle tears are commonly seen in ACL-deficient knees [5].

3.3. Mechanism of Injury

The mechanism of the injury can be classified into three categories: (1) occurring during sporting activity (e.g. basketball, football, rugby), (2) occurring during non-sport activity, and (3) occurring during no activity. In a study of 392 patients conducted in 2004 by Drosos and Pozo, the researchers found that 32.4% of patients experienced the injury during sporting activities, while a higher percentage of 38.8% of patients experienced the injury during non-sporting activities. Another around one-third (28.8%) of patients did not recognize any specified incident that led to a meniscus tear [21].

Gender is also a key risk factor. Studies have reported that the incidence rate of meniscal injury is four times higher in men than in women. This may be because men and women have slight anatomical and physiological differences in the meniscus, and have different daily activities and occupations. These all may result in different incidence rates between men and women [21].

4. Pain

Different degrees of meniscal injury have different symptoms, and there are mainly two kinds of direct and indirect symptoms. The pain is characterized by being fixed on the side of the injury, and the pain is aggravated with the increase in activity, and some patients have no obvious pain.

4.1. Direct Symptom

4.1.1. Pop

A popping sound can be heard or felt on the injured side of the meniscus when the knee is moved.

4.1.2. Point Locking

When the joint is suddenly "stuck" and cannot be stretched or flexed, it is generally rare in the acute phase, and mostly occurs in the chronic phase. After locking, the joints are sore and cannot be stretched and flexed. They can be "unlocked" by themselves or with the help of a doctor. After "unlocking", the synovial membrane is often swollen, and the interlocking feature is fixed on the injured side.

4.1.3. Swollen Joints

In the acute injury stage of effusion, there are often synovial involvement injuries or other structural injuries, often hemoarticular effusion. In the chronic phase, joint swelling is related to the amount of activity. The synovial fluid is yellow translucent synovial fluid, which is the result of chronic traumatic synovitis. The swollen joint fluid can be checked by the floating patella test and the knee joint effusion induction test.

4.1.4. Joint Space Tenderness And Protrusion

The tenderness of the joint space on the side of the meniscus injury is positive, and the tenderness points are mostly consistent with the location of the meniscus injury (such as bodily injury, tenderness is in the body), and the injured meniscus can also be touched. Meniscal eminence is meaningful for diagnosis, but should be differentiated from cysts.

4.2. Indirect Symptom

4.2.1. O-leg or X-leg

Long-term injury may induce osteoarthritis or lead to changes in the force line. Over time, it may cause O-shaped legs or X-shaped legs, which are relatively rare in clinical practice.

4.2.2. Quadriceps Atrophy

Meniscus injury has obvious symptoms, long-term untreated, can cause quadriceps muscle atrophy, and the vastus medialis muscle is more obvious [22]. It is noted that quadriceps atrophy is not a specific sign of meniscal injury.

4.2.3. Unilateral Limb Movement Disorder

Due to the refusal and inactivity of the injured knee joint due to pain, the muscle strength has decreased and decreased to a certain extent. It could cause obvious movement difficulties when going up and down steps and squatting.

4.2.4. Knee Synovitis

After the meniscus is injured, certain inflammatory stimulation could happen. After prolonged stimulation, it could cause the inflammatory exudation of the synovial tissue inside the knee joint cavity, which can be manifested as knee joint cavity effusion. The effusion in the knee joint cavity often continues to produce effusion after fluid extraction and treatment. Therefore, it is still necessary to treat meniscal injuries.

4.2.5. Intractable Pain

After the meniscus is injured, the infrapatellar branch of the saphenous nerve may be damaged, resulting in nerve damage and intractable pain in the injured knee joint [23].

5. Treatments

Most meniscal injuries should be treated with arthroscopic surgery, and partial meniscal tear removal or meniscus suture repair should be selected based on the specific conditions of the patient. It is generally divided into two categories: conservative treatment and surgical treatment.

5.1. Conservative Treatment

Conservative treatment is used for patients with minor injuries or unknown conditions. Generally, it includes general treatment such as massage, acupuncture, and slight movement, as well as drug treatment.

5.1.1. Massage

As a kind of conservative treatment, the advantage of massage is that small lacerations can sometimes be asymptomatic after the acute phase, and marginal lacerations sometimes heal on their own. The specific technique is to lie on the patient's back, relax the affected limb, massage the pain point with the left thumb of the surgeon, hold the ankle with the right hand, slowly flex the knee joint and rotate the calf inside and outside, and then straighten the affected knee, initially roll around the knee joint and the front of the thigh, rubbing and other methods to promote blood circulation, accelerate the dissipation of hematoma.

5.1.2. Acupuncture

Acupuncture can be used as an adjunctive treatment for meniscal injuries. It can stimulate local acupuncture points very well, and plays a role in promoting blood circulation and removing blood stasis, reducing swelling and pain relief, and promoting the recovery of limb function. It is noted that not all situations can use acupuncture [24].

5.1.3. Slight Movement

The treatment process of this specific method is as follows: (1) compression bandage the knee with plaster back fixation, (2) exercise quadriceps static contraction on the bed on the second day, (3) straight leg raising on the third day for medial meniscus surgery, (4) straight leg on the fifth day for lateral meniscus surgery elevate and walk on crutches with a plaster cast, (5) remove stitch in 10 days, cast out in 2 weeks, and gradually increase quadriceps strength, aiming to reduce joint swelling, pain, and damage.

5.1.4. Drug

Drugs include but are not limited to Celecoxib, Glucosamine Sulfate Capsules, Aescufen forte

5.2. Surgical Treatment

Surgical treatment is generally used for patients with more severe or deep wounds. Generally, it includes meniscus suture, partial meniscectomy, and meniscectomy.

5.2.1. Meniscus Suture Repair

For those with a tear within 5mm of the attachment around the meniscus and the front and rear feet are intact, suture surgery is first used to preserve the meniscus to the greatest extent possible to maintain normal physiological function. The suture methods include vertical mattress type, vertical layered type, horizontal mattress type, knot type, etc.

5.2.2. Partial Meniscectomy

Partial meniscectomy is suitable for barrel handle rupture, longitudinal rupture, or transverse rupture. Only the central part of the tear is excised, leaving a relatively stable surrounding meniscus sleeve or edge that significantly stabilizes the tibiofemoral joint. If the central part of the meniscus ruptures into the intercondylar fossa, it is suggested to first transversely cut the connection between the central part and the surrounding part in front, then clamp the front end of the central part, pull it into the intercondylar fossa, and cut off the central part and the posterior meniscus under direct vision corner connection.

5.2.3. Meniscectomy

When the meniscus is completely irreparable, the meniscus can be removed, but the edges of the meniscus should be preserved as much as possible. After complete meniscectomy, the short-term effect is good, but after a few years, the manifestations of secondary osteoarthritis such as joint space narrowing and osteophyte formation may occur, requiring additional rehabilitation training, drugs, or surgical treatment. Complete resection of the meniscus needs to be cautious. It is not suggested to completely remove the meniscus, because the effect of complete resection is often satisfactory in the early stage, but after several years due to serious side effects such as joint disease. Therefore, it is generally not a serious injury to the parenchyma of the meniscus or a severe meniscus fragmentation that causes a serious functional disorder of the knee joint without complete meniscectomy.

It is noted that meniscal injury disease requires short-term treatment for 4 to 6 weeks, which can generally be cured, but patients need to pay attention to regular follow-up visits and functional rehabilitation training 1 to 2 months after the end of treatment. At the same time, those who still have problems with joint function after 1 to 2 months of treatment should be re-examined.

6. Conclusion

Two crescent-shaped medial and lateral menisci play a vital job in the normal functioning and long-term health of the knee joint. They are different in shape due to their different relations with surrounding ligaments and their functions. Generally, the main functions of the meniscus include load sharing, shock absorption, stability, joint lubrication and nutrition. Meniscal injury is one of the most common sources of knee morbidity. Common types of meniscal injuries include vertical longitudinal, radial, horizontal, degenerative, and bucket-handle tears. Mechanism of meniscal injury can be categorized into three types: sporting activity, non-sporting activity, and non-activity. Gender is also a key risk factor with males holding predominance.

The main clinical manifestations of meniscus injury are a pain in the medial and lateral space of the knee joint, noose of the knee joint, snapping, and soft leg hitting. The most common manifestation is knee joint pain. Early detection, early diagnosis, and early treatment of meniscus injury are extremely important for controlling disease development, improving symptoms, and preventing complications. Meniscal injuries are mostly non-self-limiting, and conservative treatment or surgical intervention is selected depending on the severity of the injury. Patients in the acute stage can take anti-inflammatory and analgesic drugs to relieve symptoms when the pain is more obvious. Most

meniscal injuries should be treated with arthroscopic surgery, and partial meniscal tear removal or meniscus suture repair should be selected based on the specific conditions of the patient.

Reference

- [1] J.B. Sutton, *Ligaments: Their Nature and Morphology*. 2nd Edition. London: Lewis, 1897.
- [2] T.J. Fairbank, Knee joint changes after meniscectomy. *The Journal of Bone and Joint Surgery*. British volume, 1948, vol. 30-B, pp. 4. DOI: 10.1302/0301-620X.30B4.664
- [3] A. Hede, D.B. Jensen, P. Blyme, S. Sonne-Holm, Epidemiology of meniscal lesions in the knee: 1,215 open operations in copenhagen 1982-84, 1990, Vol. 61, pp 435-437, <https://doi.org/10.3109/17453679008993557>
- [4] B.E. Baker, A.C. Peckham, F. Sanborn J.C, Review of meniscal injury and associated sports. *The American journal of sports medicine*, 1985, vol. 13, pp. 1-4. DOI: 10.1177/036354658501300101
- [5] A.J.S. Fox, F. Wanivenhaus, A.J. Burge, R.F. Warren, S.A. Rodeo, The human meniscus: A review of anatomy, function, injury, and advances in treatment, *Clinical Anatomy*, 2015, vol. 28 pp. 269–287. DOI: 10.1002/ca.22456
- [6] E. Rath, J.C. Richmond, The menisci: Basic science and advances in treatment. *British Journal of Sports Medicine*, 2000, vol.34, pp. 252-257, DOI: 10.5435/00124635-200205000-00003
- [7] R.J. Last, The popliteus muscle and the lateral meniscus, *Journal of Bone & Joint Surgery British volume*, 1950, vol. 32, pp. 93-99. DOI: 10.1302/0301-620X.32B1.93.
- [8] P.E. Greis, D.D. Bardana, M.C. Holmstrom, R.T. Burks, Meniscal Injury: I. Basic Science and Evaluation, *Journal of the American Academy of Orthopaedic Surgeons*, 2002, vol. 10, pp. 168-176, DOI: 10.5435/00124635-200205000-00003.
- [9] A.S. Voloshin, J. Wosk, Shock absorption of meniscectomized and painful knees: A comparative in vivo study. *Journal of Biomedical Engineering*, 1983, vol.5, pp. 157-161. DOI: 10.1016/0141-5425(83)90036-5.
- [10] S.C. Shoemaker, K.L. Markolf, The role of the meniscus in the anterior-posterior stability of the loaded anterior cruciate-deficient knee. Effects of partial versus total excision. *Journal of Bone & Joint Surgery American Volume*, 1986, vol. 68, pp. 71-79, DOI: 10.2106/00004623-198668010-00009.
- [11] V. Musahl, M. Citak, P.F. O'Loughlin, D. Choi, A. Bedi, A.D. Pearle. The effect of medial versus lateral meniscectomy on the stability of the anterior cruciate ligament-deficient knee. *The American journal of sports medicine*, 2010, vol.38, pp. 1591-1597. DOI: 10.1177/0363546510364402.
- [12] M.A. MacConaill, The movements of bones and joints 3. The synovial fluid and its assistants. *Journal of Bone and Joint Surgery*, 1950, vol. 32, pp. 244-252. DOI: 10.1302/0301-620X.32B2.244.
- [13] G.G. Poehling, D.S. Ruch, S.J. Chabon, The landscape of meniscal injuries. *Clinics in sports medicine*, 1990, vol. 9, pp. 539-549. DOI: 10.1016/S0278-5919(20)30705-5.
- [14] B.D. Browner, J.B. Jupiter, A.M. Levine, P.G. Trafton, *Skeletal Trauma. Basic Science, Management and Reconstruction.*, 3rd Ed. Philadelphia, PA: Saunders, 2003.
- [15] R.A. Hauser, H.J. Philips, H.S. Maddela, The Case for Utilizing Prolotherapy as First-Line Treatment for Meniscal Pathology: A Retrospective Study Shows Prolotherapy is Effective in the Treatment of MRI-Documented Meniscal Tears and Degeneration. *Journal of Prolotherapy*, 2010, vol.2, pp.416-437
- [16] C.A. Helms, The meniscus: recent advances in MR imaging of the knee. *American Journal of Roentgenology*, 2002, vol. 179, pp. 1115-1122. DOI: 10.2214/ajr.179.5.1791115.
- [17] T. Magee, M. Shapiro, D. Williams, M.R accuracy and arthroscopic incidence of meniscal radial tears. *Skeletal Radiol*, vol. 31, pp. 686-689, DOI: 10.1007/s00256-002-0579-8.
- [18] K.W. Harper, C.A. Lambert, L.D. Higgins, Radial meniscal tears: significance, incidence, and MR appearance. *American Journal of Roentgenology*, 2005, vol. 185, pp. 1429-1434, DOI: 10.2214/AJR.04.1024
- [19] W.H. Jee, T.R. McCauley, J.M. Kim, D.J. Jun, Y.J. Lee, B.G. Choi, K.H. Choi, Meniscal tear configurations: categorization with MR imaging. *American Journal of Roentgenology*, 2003, vol. 180, pp. 93-97. DOI: 10.2214/ajr.180.1.1800093

- [20] A.A. Schepsis, B.D. Busconi, Sports Medicine. Lower Extremity. Lippincott Williams & Wilkins, 2006.
- [21] G.I. Drosos, J.L. Pozo, The causes and mechanisms of meniscal injuries in the sporting and non-sporting environment in an unselected population, *The knee*, 2004, vol. 11, pp. 143-149. DOI: 10.1016/S0968-0160(03)00105-4
- [22] Guzmán Venegas Rodrigo, O.D. Valencia, S. Haro, K. Ibarra, M. Jara, M. Orlandini, et al. Difference between the activation level of the vastus medialis oblique and longitudinal muscle during an open kinetic chain exercise. *Journal of Movement and Health (JMh)*, 2016, vol.17, pp. 51-53.
- [23] Frederick M. Azar MD, in *Campbell's Operative Orthopaedics*, 4th edition. Philadelphia: Elsevier, 2021
- [24] S.M. Pan, X.Y. Zhang, D.Y. Wu, Y.K. Guo, L. Ding, R.Z. Tan. Analysis of Medication Rules of TCM Prescription against Primary Hepatic Carcinoma Based on TCM Data Analysis Platform Based on Strategy Pattern. *China Pharmacy*, 2020, vol. 31, pp. 2966-2973.