

Toxicities of Pembrolizumab in Cancer Patients

Dexin Jiang^{1,†}, Yidan Lyu^{2,†}, Rui Miao^{3,†}, Ruoyun Wang^{4,*†}

¹ International Department, Kang Chiao International School, Suzhou, Jiangsu, 215332, China

² College of Pharmaceutical Sciences, Zhejiang University, Hangzhou, Zhejiang, 310058, China

³ School of Foreign Languages, China Pharmaceutical University, Nanjing, Jiangsu, 210000, China

⁴ School of Molecular and Cellular Biology, University of Leeds, Leeds, LS2 8AR, UK

* Corresponding Author Email: bs21rw2@leeds.ac.uk

†These authors contributed equally

Abstract. Pembrolizumab is a humanized anti-PD1 monoclonal antibody that has been approved for immunotherapy of malignant melanoma, classical hodgkin lymphoma, non-small cell lung cancer, etc. However, the toxicity of pembrolizumab has been demonstrated in preclinical and clinical studies. The main side effects of pembrolizumab are related to the activation of various immune cells in the body. The triggered immune system may attack healthy organs, such as the livers, lungs and kidneys. The resulting toxic reactions can cause varying degrees of damage to the patient's body and need to be taken seriously. In response to the toxic side effects of pembrolizumab, discontinuation of the drug is often taken in conjunction with symptomatic treatment, and the herb is a potentially effective drug in many related diseases. In general, the side effects of immune checkpoint inhibitors are relatively minor and serious toxicities are rare, but some of the serious toxicities are fatal. Therefore, early detection and treatment of adverse reactions are of great interest, and mechanisms as well as treatments of toxicity of pembrolizumab requires further studies.

Keywords: Pembrolizumab, Keytruda, Toxicities, Cancer.

1. Introduction

The immune system recognizes cancerous cells with the assistance of a special molecules called immune checkpoints existing on the outer side of plasma membrane of the lymphocyte [1]. To escape from the attack of immune cells, some cancerous cells interact with immune checkpoints and inactivate immune cells. To avoid this situation, immune checkpoint inhibitors were developed to remove inhibition to immune cells and enhance immune response.

The Cytotoxic T-lymphocyte-associated protein 4 (CTLA-4) inhibitor was approximately the first kind of immune checkpoint inhibitor being tested clinically [2]. In 2011, CTLA-4 inhibitor, ipilimumab, received FDA approval and became the 1st immune checkpoint inhibitor allowed to treat cancer [2, 3]. Subsequently, immune checkpoint inhibitors that act on either programmed death-1 receptor (PD-1) or the ligands of it (PD-L1) were developed. Among all PD-1 inhibitors, Pembrolizumab, with trade name of Keytruda, was the first antibody blocking PD-1 approved by FDA, which was initially utilized for dealing with metastatic or unresectable melanoma. Up to now, it has also been applied to treating non-small cell lung cancer (NSCLC), carcinoma and triple negative breast cancer etc. [3]. By blocking PD-1, Pembrolizumab prevent the binding of PD-1 and the ligands of it (Figure 1), hence remove the negative impact to T&B lymphocytes and increase the secretion of cytokines and antibodies, which in turn assist immune cells to attack cancerous cells.

Pembrolizumab, commonly acting as a second line therapy and sometimes a first line therapy, is relatively safe compared to chemotherapy and ipilimumab. However, drugs often become toxic due to overdose, using for an excessively long time or the accumulation of toxic metabolites, and so does Pembrolizumab.

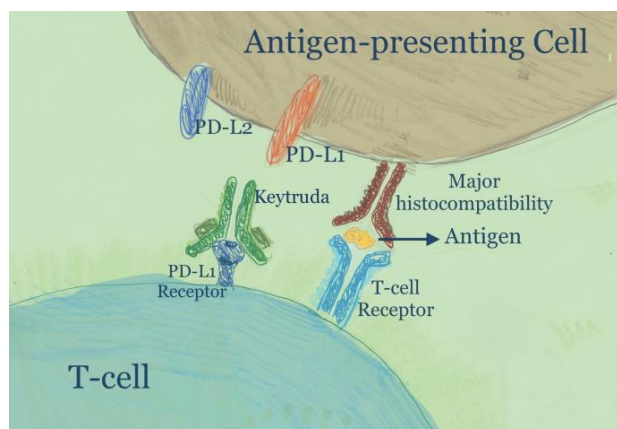


Figure 1. The mechanism of pembrolizumab

This review introduces three common toxicities, including hepatic toxicities, renal toxicities and lung toxicities, as well as three relatively rare toxicities, which are immune-related ocular toxicities, neurological toxicities and endocrine toxicities. There will also be 5 cases of adverse effects caused by pembrolizumab presented in the end of this review.

2. Common Toxicities

Even pembrolizumab is relatively safe, it can still cause immune-related adverse events (irAEs). Steroid is the first choice to relieve those irAEs [5-7]. Moreover, People with HLA-A*03 gene are more likely to suffer from irAEs when treated by pembrolizumab [4].

2.1. Liver Toxicity

Pembrolizumab activates the T cells and ensures that cancer cells would not bind to it, halting T cells [8]. However, it would trend several problems, and liver toxicity is one of those. It is a rare side effect associated with the blockade of PD-1. Less than 1% of immune-related hepatitis observed in the clinical trial of Pembrolizumab has been observed [15]. The use of checkpoints shows some unique inflammatory toxicities called irAEs. The liver toxicity use grade shows seriousness, and the grade is related to AST. Grade one is between AST 1.0-3.0, grade two is between 3.0-5.0, grade 3 is between 5.0-20.0, and grade four is at least 20 [9]. The 1% mentioned before is one of the irAEs, about the liver. Grade 3-4 toxicities at most 5%. Moreover, toxicity could occur in each organ, the skin, lung, etc[8].

As the clinical trial is an example, a 60-years-old man felt tired, had yellow urine and eyes, and had anorexia for seven days. He went to the hospital, and he was diagnosed with liver cancer. Because previous treatment on sorafenib is a failure, so he needs to end up with treatment before he chooses pembrolizumab for his treatment [10]. Furthermore, his disorder deterioration does not develop in a positive direction. A year later, he passed away [16]. There is a question: Keytruda is a drug that could be used in many cancer treatments and would have a disaster-like trend. However, Keytruda has toxic effects, and the mechanism remains unclear. Importantly, immune checkpoint inhibitors (ICIs), used familiarly in cancer now, the rate of liver toxicity increases, which becomes a problem that focuses on. Based on these mechanisms, B cells play a role in relatively toxicity. Since the early B cell changed in patients when they used ICI, after immunotherapy, it may produce autoreactive B cells, and through immune-mediated reaction, perhaps generating irAEs. Also, the gut microbiota seems to affect the onset of irAEs when patients use PD-1 or PD-L1 immunotherapy, and 50% of their condition worsens. Regulatory T cell depletion suggested playing a role in irAEs, which is essential for peripheral tolerance [11].

Furthermore, the Regulatory T cell (Treg cell) express in CTLA-4, and expression is restricted to subpopulations [11]. Inhibition of CTLA-4 could affect the amount of Treg cells and function. Moreover, a patient uses another kind of immunotherapy, ipilimumab, an anti-CTLA-4 inhibitor, a

type of checkpoint inhibitor. Preclinical irAEs have shown that Treg cells and irAEs have a negative correlation. In summary, B cells and Treg cells could be a possible reason for the toxicity of the liver, and those two relate to PD-1 and another kind of immunotherapy.

Treatment of toxic hepatitis remains unclear. Some research found that medicine made from herbs may have fewer adverse reactions. Such as silymarin, resveratrol, curcumin and ginkgo. They are the most studied natural products for in vitro liver protection [9]. Some natural products containing polyphenols were considered potential chemo-protective and hepatoprotective agents. [9]. Hence a potentially good solution is to apply the medicine made by herbs with hepatoprotection effects.

2.2. Renal Toxicity

Pembrolizumab is one of the ICI therapy drugs with profound effects, and renal toxicity is one of them [12]. According to the data having now, the frequency of kidney function loss is increasing, and the renal toxicity of pembrolizumab is 1.77%. The significant injuries induced by ICI are acute tubulointerstitial nephritis (ATN)[13]. However, another resource said that the most common histologic lesion was the acute tubular injury but acute tubulointerstitial nephritis[14]. There are several aspects of differences between the two diseases. ATN is an inflammation that affects the kidney tubes, tissues, and histologic lesions. An acute tubular injury(ATI) simplifies the tubules, which rapidly lose the glomerular filtration rate, usually with oliguria, granular casts, and low-level proteinuria.

In total have, 12 patients out of 676 are Keytruda-treated (Keytruda is the trade name for pembrolizumab). Patients (incidence 1.77%) were included (median age 69.75 years). The tested patients were referred for acute kidney injury(AKI) and proteinuria. All the patients take a kidney biopsy, starting from the median of the treatment, duration of 9 months. Biopsy results showed that four patients had acute interstitial nephritis (AIN), five had only AIN, one had minimal change disease (MCD) and ATI, and one had only MCD. ATN and ATI are similar, but the difference is that in ATN, the tubular damage is permanent. Therefore, this clinical source can be used as a reference for ATN. The most effective way to restore renal function was to discontinue pembrolizumab and treat it with corticosteroids. In patients who received pembrolizumab as maintenance therapy and continued it, the situation worsened with recurrent AIN. Two patients died from tumor progression, and one developed severe renal failure requiring dialysis [14]. Two patients died due to tumor progression, but one developed severe renal failure requiring dialysis [14].

Pembrolizumab could induce a severe kidney problems and even renal failure. It is an excellent medicine in humankind's history, but it also brings harsh effects to people after its taking. Hence may improve the medicine with herb, substitute some elements to herb, and might less toxicity for people.

2.3. Pulmonary Toxicity

A meta-analysis evaluated pembrolizumab-associated pneumonitis (in 4 of 12 clinical trials). In these studies, pembrolizumab was dosed at different doses (2 mg/kg every 3 weeks, 10 mg/kg every 3 weeks, or 200 mg every 3 weeks) [17]. Compared with nivolumab, chemotherapy-controlled treatment, placebo-controlled treatment, and everolimus-controlled treatment, pembrolizumab was associated with an increased risk of high-grade pneumonia, but only in patients receiving pembrolizumab 200 mg every 3 weeks higher [17].

Identifying pulmonary toxicity is critical, and given the nature of the disease process and treatment, diagnosis may be more challenging in lung cancer patients. Identifying pulmonary toxicity is critical, and given the nature of the disease process and treatment, the diagnosis of lung cancer patients can be more challenging. Pembrolizumab induces de novo development or reactivation of pulmonary granulomas or sarcoidosis, but its diagnosis is particularly challenging because it may mimic the progression of malignancies such as new lung lesions (parenchymal infiltrates) and mediastinal and hilar lymphadenopathy development of. However, sarcoidosis has an increased affinity for fluorodeoxyglucose in positron emission tomography/computed tomography [18, 19]. This is the same with most malignant tumors. Therefore, tissue biopsies are often required to differentiate tumor

disease progression from immunotherapy-related sarcoidosis. Multiple case reports have been published describing pembrolizumab-related organizing pneumonia. The main pathological changes of organizing pneumonia are the respiratory bronchioles and the following small airways and organizing pneumonia in alveolar spaces. Pulmonary function is primarily characterized by restrictive ventilatory disturbances, and hypoxemia at rest and after exercise is a common feature. Two pembrolizumab-related cases involved two patients with metastatic melanoma in their 80s, and the other involved a 64-year-old woman with stage IV mucosal melanoma who received pembrolizumab as an opportunity for third-line therapy [20, 21]. In the first case, the patient had previously taken temozolomide and then started pembrolizumab 10 mg/kg every 3 weeks. In the second case, the patient had previously undergone surgery and radiotherapy, and then started Pembrolizumab 2 mg/kg every 2 weeks [20]. Two patients developed dyspnea and cough after 11 and 4 cycles, respectively. Withdrawal and oral prednisolone improved symptoms and radiology. A third patient had been previously treated with dacarbazine and ipilimumab [21]. After 4 cycles, the diagnosis was consistent with OP, and pembrolizumab was discontinued. Since then, the patient's clinical and radiological presentation has improved rapidly [21]. Early identification of OP is important in any patient receiving pembrolizumab who develops new symptoms of cough or shortness of breath.

There are also case reports of Pembrolizumab-Related Pulmonary Infection Reactivation (TB), Fatal Steroid-Resistant Airway Inflammation (Severe Fatal Asthma Exacerbation), Alveolar Hemorrhage Related to Pembrolizumab, etc [22-24].

2.4. Other Toxicities

2.4.1. Immune-related Ocular Toxicity

Currently published clinical guidelines for the management of immune-related adverse events focus on more common toxicities such as liver, kidney, and lung. However, treatment of less common toxicities such as uveitis and dry eye is not adequately covered. Thus, the fact remains that ocular adverse events, in particular, may contribute to a worsening of quality of life and may affect patient compliance with treatment.

In a randomized phase II study in advanced melanoma (including 528 patients), a randomized phase II study in advanced non-small-cell lung cancer (including 1033 patients), a randomized phase I study in advanced melanoma (included 173 patients), and two nonrandomized studies including 788 patients in advanced melanoma reported various forms of immune-related ocular toxicity associated with pembrolizumab [25]. Although immune-related ocular toxicity is uncommon, immune-related uveitis and dry eye occur more frequently in cancer patients treated with pembrolizumab and other immune checkpoint inhibitors than in control regimens [25].

2.4.2. Immune-related Neurological Toxicity

Neurologic IrAE is a rare complication of pembrolizumab that can lead to long-term morbidity. These adverse effects are caused by autoimmunity caused by upregulation of T cell activity. There is a case report of a patient with neuroviral pneumonia in the mk-3475 trial. ML-3475 trial (Merck, Kenilworth, NJ) investigated the use of first-line pembrolizumab versus standard chemotherapy (KEYNOTE-024, ClinicalTrials.gov identifier NCT02142738). Patients received carboplatin (500 mg/ml/min in the concentration-time curve region) and pemetrexed (500 mg/m² every 3 weeks) for 4 cycles, followed by maintenance pemetrexed (every 3 weeks) 500 mg/m² weekly). The patient then received 2 cycles of maintenance therapy and was transferred to pemetrexed (200 mg IV every 3 weeks). Four days after the second cycle of pemetrexed, he was hospitalized with sudden onset of somnolence, confusion, ataxia, expressive language impairment, and cognitive impairment [26]. The patient achieved a durable disease response despite discontinuation of treatment. Although corticosteroid therapy is sensitive to neurotoxicity, neurotoxicity is often associated with long-term disability and must be taken seriously.

2.4.3. Endocrine Toxicity

Pembrolizumab induced irAEs may affect the endocrine system, which in turn may affect many organs and tissues, and may cause manifestations such as respiratory, gastrointestinal, cutaneous and endocrine toxicity. A multi-center retrospective study analyzed the occurrence and development of various cancers in 179 patients who could receive PD-1 inhibitors nivolumab and pembrolizumab [27]. Endocrine toxicity occurred in 54 (30.2%) of 179 patients, including 29-year-old men (53.7%) and 25 females (46.2%), indicating no significant gender differences [27]. Most thyroid toxicity occurred within 5 months of anti-PD-1 therapy [27]. The findings of this study are consistent with those of the largest series involving the largest number of patients published to date. Routine monitoring of thyroid function, with increased frequency during the first few months of palivizumab therapy, is recommended, with a higher risk of endocrine toxicity.

2.4.4. Other Cases

In addition to the toxicities described above, many other side effects have been reported in patients receiving pembrolizumab. Table 2. lists some of the cases of pembrolizumab toxicity reported in recent years.

Table 1. Rare pembrolizumab treatment induced toxicities reported in case reports

Case	Patient	Symptoms	Treatment	Reference
Myasthenia gravis	A 63-year-old male (with no prior myasthenia gravis history)	Right eyelid drooping, puffiness, blurred vision, and shortness of breath	Aggressive treatment with corticosteroids, pyridostigmine, intravenous immunoglobulin, and plasmapheresis	[28]
Acquired generalized lipodystrophy	A 67-year-old male	Loss of subcutaneous fat, unexplained weight loss in combination with insulin resistance and worsening hypertriglyceridemia	Continued to receive pembrolizumab given stabilization and melanoma treatment	[29]
Isolated adrenocorticotropin deficiency	A 78-year-old man	3-day-long fever, anorexia, and vomiting	Improved by 10 mg per day of hydrocortisone treatment	[30]
Inflammatory myeloradiculitis	A 73-year-old man	Developed acute on chronic lumbar back pain with no inciting trauma, asymmetrical grade 3 paraesthesia of the upper and lower limbs, and hypoesthesia and hypoalgesia in a banded distribution extending from the T10 to L1 dermatomes	Pembrolizumab was discontinued and neurooncological investigations commenced	[31]
Pancytopenia	A 52-year-old Caucasian woman	Colitis, hepatitis, gastritis, vitiligo, knee synovitis and then severe pancytopenia	Via a combination of corticosteroids and intravenous immunoglobulins	[32]

3. Conclusion

Given the growing popularity of immune checkpoint inhibitors, more attention needs to be focused on the toxic side effects that may occur during treatment. As more indications for pembrolizumab are identified, more and more patients with melanoma or other types of tumors will be treated with immunotherapy, and vigilance is needed in identifying and treating these side effects. Pembrolizumab treatment may cause three common types of toxicity, including hepatotoxicity, nephrotoxicity, and pulmonary toxicity, as well as some rare immune-related toxicity. Liver toxicity is a rare side effect associated with blockade of PD-1 and is potentially treatable with herbs that have hepatoprotective properties. Pembrolizumab-induced kidney injury is generally treated with discontinuation of pembrolizumab in combination with corticosteroids, and herbal remedies are also a potential approach. Other immune-related adverse reactions such as pulmonary toxicity, ocular toxicity, neurotoxicity and endocrine toxicity also require early detection and treatment. These toxic effects often occur early in treatment and often lead to rapid clinical deterioration. Therefore, regular monitoring and check-ups are undoubtedly necessary during the treatment with Pembrolizumab. The correct diagnosis of the cause of adverse effects in these patients is crucial for their quality of life and treatment outcome. The increasingly widespread use of immunotherapy urges further work to elucidate the toxicity of immunotherapy and the long-term effects of treatment.

REFERENCES

- [1] J. McLachlan, Immune checkpoint inhibitors and their side effects. *Pathology*. 2018, Vol.51, pp.S17-S17. DOI: <https://doi.org/10.1016/j.pathol.2018.12.036>
- [2] K. Shih, H.T. Arkenau, J.R. Infante, Clinical Impact of Checkpoint Inhibitors as Novel Cancer Therapies. *Drugs*, 2014, vol.74. DOI: <https://doi.org/10.1007/s40265-014-0305-6>
- [3] [3] L. Khoja, M. O. Butler, S. P.Kang, S. Ebbinghaus, A. M. Joshua, Pembrolizumab. *Journal for immunotherapy of cancer*, 2015, Vol. 3 (1), e 416-946-4501. DOI: <https://doi.org/10.1186/s40425-015-0078-9>
- [4] V. Naranbhai, M. Viard, M. Dean, S. Groha, D. A. Braun, et al. HLA-A*03 and response to immune checkpoint blockade in cancer: an epidemiological biomarker study. *The Lancet. Oncology*, 2022, Vol. 23(1), pp.172–184. DOI: [https://doi.org/10.1016/S1470-2045\(21\)00582-9](https://doi.org/10.1016/S1470-2045(21)00582-9)
- [5] I. Faisal, M. Masab, S. Gupta, W. Ullah, New drugs and new toxicities: pembrolizumab-induced myocarditis, *BMJ case reports*, 2018, Vol.2018, p.bcr-2017-223252. DOI: <http://dx.doi.org/10.1136/bcr-2017-223252>
- [6] H. Izzedine, A. Mathian, S. Champiat, C. Picard, C. Mateus, E. Routier, A. Varga, D. Malka, A. Leary, J. Michels, J. M. Michot, A. Marabelle, O. Lambotte, Z. Amoura, J. C. Soria, S. Kaaki, N. Quillard, J. M Goujon, I. Brocheriou, (2019). Renal toxicities associated with pembrolizumab. *Clinical kidney journal*, 2019, Vol.12(1), pp.81–88. DOI: <https://doi.org/10.1093/ckj/sfy100>
- [7] A. Marjanska, P. Galazka, M. Marjanski. M., Wysocki, J. Styczynski, Efficacy and Toxicity of Pembrolizumab in Pediatric Metastatic Recurrent Melanoma. *Anticancer Research*, 2019, Vol. 39 (7), pp.3945-3947. DOI: <https://doi.org/10.21873/anticancer.13547>
- [8] B. Calderon, et al. Pembrolizumab Treatment-Induced Liver Toxicity. *Case Reports in Gastroenterology*, no. 2, 2021, pp. 742–50. DOI: <https://doi.org/10.1159/000518128>
- [9] D. Singh, et al. Drug-Induced Liver Toxicity and Prevention by Herbal Antioxidants: An Overview, *Frontiers in Physiology*, 2016, pp. 363, DOI: <https://doi.org/10.3389/fphys.2015.00363>
- [10] Z. Wu, et al. Acute Liver Failure Caused by Pembrolizumab in a Patient with Pulmonary Metastatic Liver Cancer. *Medicine*, no. 51, 2017, pp. e9431. DOI: <https://doi.org/10.1097/md.0000000000009431>
- [11] Eleonora. De Martin, et al. Liver Toxicity as a Limiting Factor to the Increasing Use of Immune Checkpoint Inhibitors, *JHEP Reports*, no. 6, 2020, pp. 100170. DOI: <https://doi.org/10.1016/j.jhepr.2020.100170>

- [12] W. D. Dumoulin, et al. Renal Toxicity from Pemetrexed and Pembrolizumab in the Era of Combination Therapy in Patients with Metastatic Nonsquamous Cell NSCLC. *Journal of Thoracic Oncology*, 2020, pp. 1472–83. DOI: <https://doi.org/10.1016/j.jtho.2020.04.021>
- [13] R. Raghavan, and E. Garabed. Acute Interstitial Nephritis a Reappraisal and Update, *Clinical Nephrology*, no. 3, Dustri-Verlag Dr. Karl Feistle, 2014, pp. 149–62. DOI: <https://doi.org/10.5414/cn108386>
- [14] B. Sprangers. Pembrolizumab-Related Renal Toxicities: Diagnosis First, Treatment Later. *Clinical Kidney Journal*, no. 1, 2018, pp. 78–80. DOI: <https://doi.org/10.1093/ckj/sfy114>
- [15] H. Izzedine, A. Mathian, S. Champiat, C. Picard, C. Mateus, et. al. Renal toxicities associated with pembrolizumab, *Clinical kidney journal*, 12(1), 2018, pp. 81–88. DOI: <https://doi.org/10.1093/ckj/sfy100>
- [16] L. Spain, S. Diem, and J. Larkin. Management of toxicities of immune checkpoint inhibitors, *Cancer Treatment Reviews*, 2016, pp. 51–60, ISSN 0305-7372. DOI: <https://doi.org/10.1016/j.ctrv.2016.02.001>
- [17] P. Cui, J. Ma, F. Wang, et al., Pneumonitis and pneumonitis-related death in cancer patients treated with programmed cell death-1 inhibitors: a systematic review and meta-analysis, in: *Proceedings of the Therapeutics and Clinical Risk Management*, 2017, pp. 1259-1271. DOI: <https://doi.org/10.2147/TCRM.S143939>
- [18] A. Majdi, M. Mohammed. S. Ibrahim, et al., Pembrolizumab reactivates pulmonary granulomatosis, in: *Proceedings of the Respiratory medicine case reports*, 2017, pp. 126–129. DOI: <https://doi.org/10.1016/j.rmcr.2017.07.010>
- [19] C. Jonathan; Q. Christiane; B. William J; R. Naveen, et al., Pembrolizumab-associated sarcoidosis, in: *Proceedings of the JAAD Case Reports*, 2016, pp. 290-3. DOI: <https://doi.org/10.1016/j.jdcr.2016.06.004>
- [20] L. Vincent; T. Carole; F. Jean-Baptiste; S. Arnaud, et al., Pembrolizumab-induced pneumonitis, in: *Proceedings of the ERJ open research*, 2017, pp. 00081-2016. DOI: <https://doi.org/10.1183/23120541.00081-2016>
- [21] F. Paraskevi; S. Maria; T. Maria; K. Christina, et al., A Case of Organizing Pneumonia (OP) Associated with Pembrolizumab, in: *Proceedings of the Drug Target Insights*, 2016:10, pp. 9-12. DOI: <https://doi.org/10.4137/DTI.S31565>
- [22] JJX. Lee, A. Chan, T. Tang, Tuberculosis reactivation in a patient receiving anti-programmed death-1 (PD-1) inhibitor for relapsed Hodgkin’s lymphoma, in: *Proceedings of the Acta Oncologica*, 2016, pp. 519-520. DOI: <https://doi.org/0.3109/0284186X.2015.1125017>
- [23] T. Ogawa, J. Miyata, J. Maehara, et al., Fatal airway inflammation induced by pembrolizumab in a patient with NSCLC, in: *Proceedings of the Journal of Thoracic Oncology*, 2019, pp. e9-e10. DOI: <https://doi.org/10.1016/j.jtho.2018.09.002>
- [24] T. Sugano, M. Seike, R. Noro, et al., A case of interstitial lung disease with alveolar hemorrhage induced by pembrolizumab, in: *Proceedings of the Oncotargets and Therapy*, 2018, pp. 5879-5883. DOI: <https://doi.org/10.2147/OTT.S169321>
- [25] O. Abdel-Rahman, H. Oweira, U. Petrausch, D. Helbling, et al., Immune-related ocular toxicities in solid tumor patients treated with immune checkpoint inhibitors: a systematic review, in: *Proceedings of the Expert Review of Anticancer Therapy*, 2017, pp. 387-394, DOI: <https://doi.org/10.1080/14737140.2017.1296765>
- [26] S. Feng, J. Coward, E. McCaffrey, J. Coucher, et al., Pembrolizumab-Induced Encephalopathy: A Review of Neurological Toxicities with Immune Checkpoint Inhibitors, in: *Proceedings of the Journal of Thoracic Oncology*, 2017, pp. 1626-1635, DOI: <https://doi.org/10.1016/j.jtho.2017.08.007>
- [27] E.M. Presotto, G. Rastrelli, I. Desideri, et al., Endocrine toxicity in cancer patients treated with nivolumab or pembrolizumab: results of a large multicentre study, in: *Proceedings of the Journal of endocrinological investigation*, 2020, pp. 337–345. DOI: <https://doi.org/10.1007/s40618-019-01112-8>
- [28] K.L. March, M.J. Samarin, A. Sodhi, R.E. Owens, Pembrolizumab-induced myasthenia gravis: A fatal case report, in: *Proceedings of the Journal of Oncology Pharmacy Practice*, 2018, pp. 146–149. DOI: <https://doi.org/10.1177/1078155216687389>
- [29] B. Sara, G.T. Christie , R.L. Victor, S.T. Kim , N.T. Sonali, A case of acquired generalized lipodystrophy associated with pembrolizumab in a patient with metastatic malignant melanoma, in: *Proceedings of the AACE clinical case reports*, 2020, pp. e40-e45. DOI: <https://doi.org/10.4158/accr-2019-0234>

- [30] K. Yamamoto, K. Tokumasu, K. Oka, K. Hasegawa , F. Otsuka, Isolated adrenocorticotropin deficiency induced by pembrolizumab for hypopharyngeal cancer: A case report, in: Proceedings of the Clinical case reports, 2021, pp. e04305-e04305. DOI: <https://doi.org/10.1002/ccr3.4305>
- [31] M.L. Vickers, B. Seidl, K. Bigby, B. Chern, et al., Inflammatory Myeloradiculitis Secondary to Pembrolizumab: A Case Report and Literature Review, in: Proceedings of the Case reports in oncological medicine, 2020, pp. 8819296-8819296. DOI: <https://doi.org/10.1155/2020/8819296>
- [32] A. Dinesh, P.J. Krishna, R. Rahul, M. Fade, Pembrolizumab-Induced Pancytopenia: A Case Report, in: Proceedings of the The Permanente journal, 2017, pp. 17-004. DOI: <https://doi.org/10.7812/tpp/17-004>