

The Toxicity of Osimertinib in Cancer Therapy

Hanqi Chen^{1, †}, Hao Chen^{2, *, †}, Rui Deng^{3, †}, Chenhuan Zhu^{4, †}

¹ School of Biological Science, University of Manchester, Manchester M14 5TE, UK

² School of Chemistry, University of Manchester, Manchester M14 5TE, UK

³ School of Life and Medical Sciences, University College London, London WC1E 6BT, UK

⁴ School of Science, Xi'an Jiaotong-Liverpool University, Suzhou 215123, China

* Corresponding Author Email: hao.chen-18@student.manchester.ac.uk

†These authors contributed equally.

Abstract. Osimertinib is a novel 3rd-generation TKI which targets the EGFR in NSCLC. It inhibits the phosphorylation of EGFR, thereby inhibits proliferation of NSCLC. Thus, Osimertinib is widely used in the treatment of lung cancer, as well as other types of cancers such as glioblastoma (GBM). However, there are still some drawbacks. Osimertinib can suppress stromal cells in the bone marrow, thereby leading to the aplastic anaemia. Osimertinib can also contribute to dermatosis. Some patients are diagnosed with kidney and heart failure after the treatment, which is suspected the failures associated with the Osimertinib. Even though the drug resistance of Osimertinib is relatively low, the drug resistance cannot be completely ignored. The mechanisms of drug resistance include EGFR-dependent mechanism with the loss of T790M mutation, as well as non-EGFR-dependent mechanism due to the amplification of allele wt-EGFR and existence of allele EGFR-ex19del. In addition, the price of Osimertinib is still high in most regions. Future studies may focus on how to reduce the toxicity to organs and the drug resistance, thereby providing a direction for the fourth-generation TKI.

Keywords: Toxicity, Osimertinib, Adverse Effect, Tolerance, Cardiotoxicity, Nephrotoxicity

1. Introduction

Lung cancer is nominated as one of the most common and lethal cancers, accounting for 1.6 million annual cancer-related global death. Because of curable oncogenic changes and the possibility of tailored treatment, lung cancer in non-smoking people has piqued the interest of researchers. Lung cancer is classified into two subtypes: SCLC, which contributes 15% of all new cancer cases, and NSCLC, which is a heterogeneous cancer that includes adenocarcinoma (gland-forming), squamous cell carcinoma, and large cell carcinoma histo-subtypes and accounts for approximately 85% of cases [1]. Investigations have indicated that EGFR and EGF-like peptides domain are frequently over-expressed in cancer and may cause cell transformation. Around two-thirds of EGFR (epidermal growth factor receptor) mutation-positive patients who experienced the disease progression after receiving the treatment of an EGFR TKI (tyrosine kinase inhibitor) was diagnosed with the T790M resistant mutation, which is a genetic mutation that induces EGFR TKI treatment resistance. Osimertinib is an irreversible, oral, 3rd-generation mutant-selective EGFR TKI, which is intended to selectively target and suppress both activating sensitizing mutant EGFR and T790M [2]. Furthermore, Osimertinib has high blood-brain barrier penetration and potentially treat brain cancers [3].

This review discusses the aplastic anaemia and dermatosis as cases of toxicity of Osimertinib on NSCLC treatment; the effect on cardiac, specifically QT prolongation; the adverse effect on kidney with the usage of Osimertinib; and finally demonstrates the drug resistance and clinical manifestation.

2. Adverse effect and toxicity of Osimertinib on NSCLC

When compared to clinical experience and historical data with other EGFR TKIs, Osimertinib had less dermatologic and gastrointestinal symptoms, according to its safety profile collated from various

clinical trials. The most prevalent side effects of Osimertinib were diarrhoea (47%), rash on skin (40%), nausea or vomiting (22%), reduced appetite (21%), as well as hematologic abnormalities (11%). The prevalence of grade 3–5 hematologic toxicities, on the other hand, was less than 2% [4].

2.1. Aplastic Anaemia

Aplastic anaemia is distinguished by its clear pathophysiology and the direct manifestation of clinical symptoms, which are classified as pancytopenia with fatty or empty bone marrow [5]. In 2019, aplastic anaemia was first discovered as a side effect of taking Osimertinib in a 74-year-old Caucasian patient who was diagnosed with advanced lung adenocarcinoma with lung and treated with Osimertinib as 1st-line treatment [6]. The patient had no smoking history or any prevalent medical information. After 21 weeks of Osimertinib administration (80mg/day), petechiae and epistaxis appeared on the patient. Severe pancytopenia was revealed by a blood test, with grade 2 anaemia (9.5g/dL), grade 4 absolute neutrophil count (ANC) (50×10^6 cells/L) and grade 4 platelet count decreased (10×10^8 cells/L). The haematological exam revealed a tiny number of circulating reticulocytes and excluded iron B12 folate deficiency. To preclude acute leukaemia and myelophthisic anaemia, the bone marrow aspiration was not given. A CT scan was conducted to exclude the possibility that the pancytopenia was caused by disease progression, and it was revealed that the partial response had been maintained and there was no splenomegaly. The patient refused to take any medicines or natural supplements at this stage, which excluded the infectious causes. A left iliac spine bone biopsy revealed significant hypoplastic bone marrow with no stromal destruction as well as haematopoiesis. Osimertinib-induced severe aplastic anaemia was diagnosed in the absence of other explanations. To activate the bone marrow, the patient was treated with high-dose steroid treatment and filgrastim for seven days and three days respectively. Despite therapy, the haematologic parameters worsened throughout hospitalisation. Daily transfusion was required but it did not play a role. The patient gradually developed neutropenia, his clinical circumstances progressively worsened till death, though a series of antibiotic treatments were provided.

Bone marrow aplasia is commonly considered associated with some specific drugs [7]. Because no alterations in blood cells were observed during the start of medication treatment, it is extremely improbable that hematopoietic progenitor cells are directly affected by Osimertinib in the bone marrow. Generally, stromal cells promote the differentiation, viability, and proliferation of stem and progenitor cells. Numerous lymphokines and cytokines are produced, after the irritating antigens assaulting the cells in the bone marrow, inhibiting haematopoiesis. In this case, Osimertinib has the potential to be an irritant antigen in the bone marrow [8]. Hence, it is acceptable to infer that the activity of stromal cells may be significantly suppressed by the Osimertinib. The bone cancer cell infiltration and concurrent palliative bone radiotherapy might be minor complicating variables leading to this major AE. Furthermore, the confounding factors of previous therapy were excluded by the 1st-line setting of Osimertinib. Medical practitioners need to realise that aplastic anaemia is an unusual but lethal side effect of this drug. The changes in blood cell count can be treated as a precaution to prevent this side effect. After two months of therapy, extensive monitoring of blood tests may be beneficial for early identification [5].

2.2. Dermatoposis

The usage of EGFR-TKI treatment is related to a high rate of dermatologic adverse events (dAEs). Acneiform rash, pruritus, xerosis, and paronychia are common side effects of 1st- and 2nd-generation agents. The regulation of dAEs correlated to Osimertinib treatment is comparable to previous generations of EGFR-TKIs. However, it differs depending on the severity of the occurrence. Because there is generally only a short amount of time between the conclusion of the 1st EGFR-TKI therapy and the beginning of Osimertinib, patients will frequently require ongoing care of dAEs as a result of the residual effects of initial 1st- and 2nd-generation EGFR TKIs [9]. The acneiform rash results from the differences in both frequency and severity that induced by 1st- and 2nd-generation EGFR-TKIs and Osimertinib. However, safety is not guaranteed even if acneiform rash rarely occurs during the

Osimertinib treatment. The symptoms typically appear in areas with hideosity of sebaceous glands [10]. Pruritus is frequently described in association with papulopustular (acneiform) rash and dry skin in patients using 1st- and 2nd-generation EGFR TKIs. It may appear after 14 days of beginning EGFR-TKI therapy or after 30 to 60 days of therapy [11]. Pruritus caused by Osimertinib is unusual because it frequently arises when rash does not occur, and the severity of this pruritus varies. The xerosis caused by Osimertinib is usually mild to moderate [10]. Pruritus, fine scaling, and fissures are all symptoms of xerosis [11]. While seldom severe or mortal, dermatologic toxicities can cause physical and mental morbidity in individuals.

3. Rare Toxicities

3.1. Cardiotoxicity

The cardiotoxicity caused by Osimertinib has been rarely reported and discussed. There was a case of congestive heart failure. A 78-year-old patient was diagnosed as wild exertional dyspnea 21 days after beginning the treatment of EGFR T790M-positive NSCLC with Osimertinib. She had been diagnosed with heart failure [12, 13]. Although the explanation of Osimertinib causing cardiotoxicity was unclear, there is a similar mechanism with trastuzumab which is well-associated with cardiomyopathy [16]. The cardiac myocyte that has a function to stress is mediated by the NRG-1/ErbB axis through Akt-dependent anti-apoptotic effects and other pathways. Ligands such as NTG-1 will activate the Erb family receptor and cause the homo- and/or heterodimerization partners to phosphorylate and finally lead to sending a signal to the Ras- ERK, and PI3-kinase- AKT pathway. Trastuzumab will prevent ErbB4 which is activated by NRG-1 heterodimerized with a preferred signaling partner ErbB2 (HER2). This will perturbative the NRG-1/ErbB axis [14]. Osimertinib may also inhibit HER2 as well as mutant EGFR, thereby potentially resulting in cardiotoxicity.

3.2. Nephrotoxicity

In a case report, a patient who was prescribed the Osimertinib (80mg/day) to treat the lung cancer is diagnosed with the induced kidney injury [15]. Before this treatment, the protein and occult test for the urine of the patient are negative and positive (1+), respectively. The renal function of this patient was normal, with a serum creatinine (Cr) level of 0.64 mg/dL. However, the increase of serum Cr levels (0.64 to 1.13 mg/dL), proteinuria, and elevated urine occult blood (1+ to 2+) occurred after the treatment of Osimertinib, these symptoms signify the raise of impaired renal function, and all of them decreased after the reduction of the dose of Osimertinib (40mg/day), which indicates this impaired renal function is not permanent, it is reversible after the withdrawal of Osimertinib [15]. The biopsy, taken in day 93 of Osimertinib administration, of the kidney of this patient was analysed as the induced kidney injury was not resulted from IgA nephropathy. These evidences confirmed that the induced kidney injury is related to the Osimertinib dose, and Osimertinib 80mg plus savolitinib 600mg or 300mg daily will lead to acute renal failure and death [16].

Patients with diarrhoea may also suffer from renal toxicity of Osimertinib, and even renal failure [17]. The EGFR controls the ionic transport of cells, and the anti-EGFR TKI will inhibit the EGFR, and then the restriction of the chlorine secretion occurs, which might contribute to the diarrhea [17-20]. The diarrhea will elevate the amount of urea and creatinine in serum, and sometimes result in the renal failure [21]. Hence, the diarrhea is one of the most severe causes of reduced renal perfusion and requires closely attention in clinic.

The regulation of Osimertinib is the key factor to decrease the adverse effect on kidney. Before the treatment, the most suitable dosage should be taken. To obtain this goal, the calibration might be a good method, finding the relationship between the serum creatinine and the dose of Osimertinib for every patient. After the determination of the allowed serum creatinine change interval, the suitable dose is obtained. Moreover, though the kidney is under observation, other disorders caused by Osimertinib, such as hypertension, should be also taken into consideration.

4. Drug-Resistance

Apart from the toxicities of Osimertinib on lung or kidney in NSCLC patients, drug-resistance of Osimertinib is another problem. To find potential therapeutic schedules to treat patients who are eaten up with Osimertinib-tolerance, the mechanism of drug-resistance is discussed (Figure 2).

Although Osimertinib exhibits wonderful curative effects in first-line treatment and dealing with secondary T790M mutation or brain metastases, the emergence of acquired drug-resistance of OSIMERTINIB is ineluctable. Due to the artificial selection given by the drug effects of Osimertinib and the inherent tumor heterogeneity of NSCLC, there are complex possibilities for Osimertinib tolerance. Briefly, these possibilities can be classified into two groups: EGFR-dependent mechanisms and non-EGFR-dependent mechanisms [2, 22].

4.1. EGFR-dependent mechanisms

Among EGFR-dependent mechanisms, the most typical mechanism is the loss of T790M mutation. The manifestation of T790M-mutation loss is tolerance to second-line treatment of Osimertinib, which always leads to shorter withdrawal time and early-period resistance of Osimertinib.

Additionally, the loss of EGFR itself may contribute to Osimertinib-resistance by enhancing the ERK and AKT to be phosphorylated [23].

Apart from these two losses, another group also account for a large proportion: tertiary EGFR mutation, dominated by mutation in C797S. On the codon 797, serine substitutes the cysteine in the ATP-binding site of exon 20, preventing Osimertinib from forming covalent bonds with EGFR mutations in ATP-binding domain [2, 22]. There are two kinds of C797S mutation, cis-mutation, and trans-mutation, decided by the location of C797S mutation (Figure 1) [24].

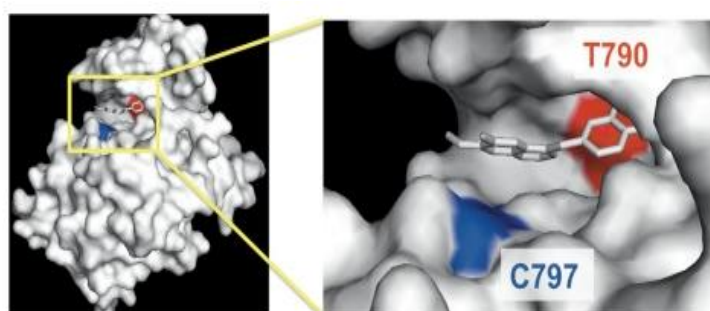


Figure 1 The relative location of C797 to T790 on EGFR [24]

Other than these two factors, there are many infrequent EGFR point mutation resulting in drug-resistance of Osimertinib, including G796, G719A, L792, L718 and G724S. The solvent-front mutations of G796 residues, the replacement of L718 residues and G719A residues nearby may lead to space limitation, interfering the combined action of Osimertinib and EGFR [2]. The mutation of L792 residues can also interfere the methoxy groups on the benzene rings of Osimertinib spatially, breaking the bindings to EGFR [2]. The mutation of G724S locates at the P-loop in EGFR kinase domain, inducing conformational changes in receptors and impairing the bindings of Osimertinib [23].

A new EGFR-dependent mechanism has already been discovered: the amplification of allele wt-EGFR and existence of allele EGFR-ex19del. Its concrete mechanism remains unknown.

4.2. Non-EGFR-dependent mechanisms

Among non-EGFR-dependent mechanism, the activation of alternative pathways occupies the main position. MET amplification can continue activating EGFR-downstream signal paths mediated by MAPK, STAT or PI3K-Akt/mTOR. HER2 amplification may encode ErbB2, activating PI3K-Akt/mTOR and MEK-ERK/MAPK pathways downstream [2]. These pathways can up-regulate the expression of PD-L1 on the cell surface, promoting tumor escape and induce idiosyncratic reactions in Osimertinib [24]. Another signaling pathway related to IGF1R activated by autocrine IGF2 may also lead to Osimertinib tolerance, which can stop tumor cell apoptosis [22, 25].

Phenotypic and histological transformation is another important factor of Osimertinib tolerance. SCLC transformation resulting from devitalized RB1 & TP53 and EMT arising from up-regulated Zeb-1 & AXL are two major types [2, 22].

Furthermore, there are several new-found mechanisms such as genetic changes encoding cyclin, fusion of oncogenes and autocrine loop of FGFR1 and FGF2 [2].

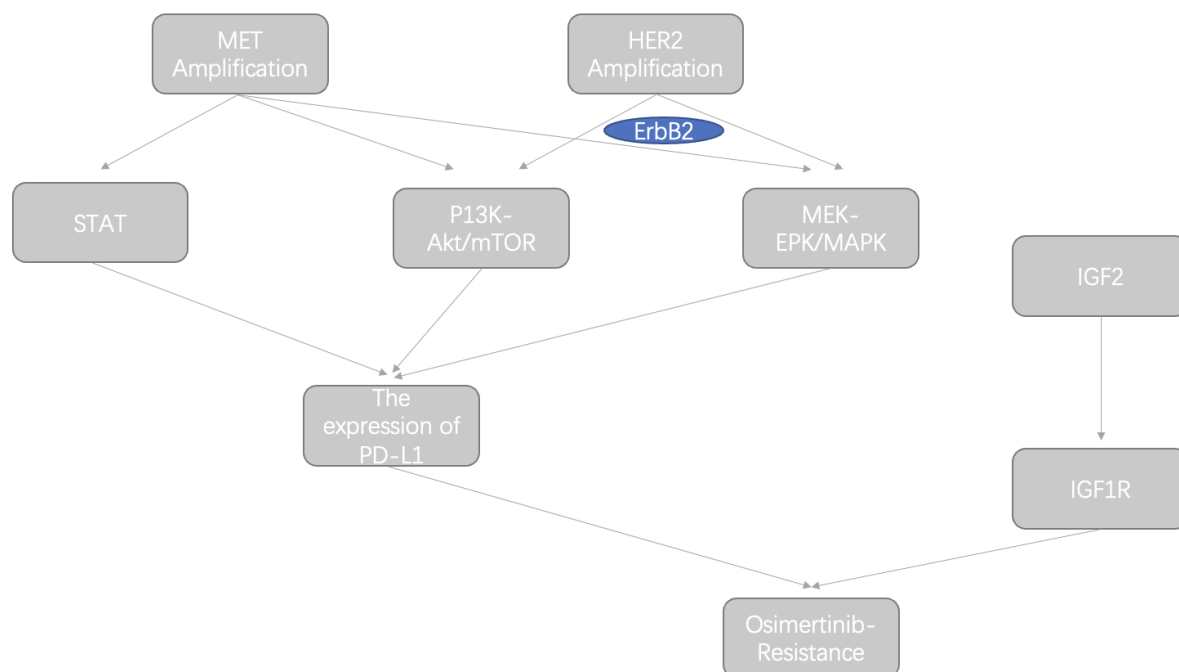


Figure 2 The mechanisms of Osimertinib resistance

Table 1. The clinical data and outcomes of patients with resistance to Osimertinib [26]

	Retained T790M	T790M+ /19del+	T790M+ /L858R+	T790M loss	EGFR-dependent	EGFR-independent
Number of patients	24	30	17	25	22	11
Proportion	24/49, 48.98%	30/49, 61.22%	17/49, 34.69%	25/49, 51.02%	22/49, 44.90%	11/49, 22.45%
Median PFS (months)	9.3	9.3	8.5	7.8	13.5	8.2
DCR	/	100.00%	93.80%	/	/	/
mTD (months)	20.2	/	/	10.5	16.6	9.5

DCR = Disease control rate; PFS = progression-free survival

4.3. The potential therapies to Osimertinib-resistance and fourth-generation EGFR-TKI

Since the heterogeneity and complexity of Osimertinib-tolerance, the potential therapies are also diverse. For instance, first-generation EGFR-TKIs can be applied to treat Osimertinib-tolerance induced by loss of T790M, but may fail when other alternative resistance mechanisms co-exist with loss of T790M [2]. Under such circumstances, multiple treatments should be adopted together.

A newly screened kinase inhibitor Brigatinib (Figure 3) can treat C797S-T790M-L858R and C797S-T790M-ex19del by ATP-competitive mode with its phosphine oxide, phosphine chloride and methoxy groups [27, 28]. Several EGFR allosteric inhibitors (4th-generation EGFR-TKI) like EAI045 and JBJ-04-125-02 can cure C797S tertiary-mutation cells too [2]. Moreover, Navitoclax (Figure 3),

a BcI-2 small-molecule inhibitor, may have the potential to treat SCLC transformation and loss of EGFR because it can induce apoptosis and restrain cell viability of these OSIR cells [29].

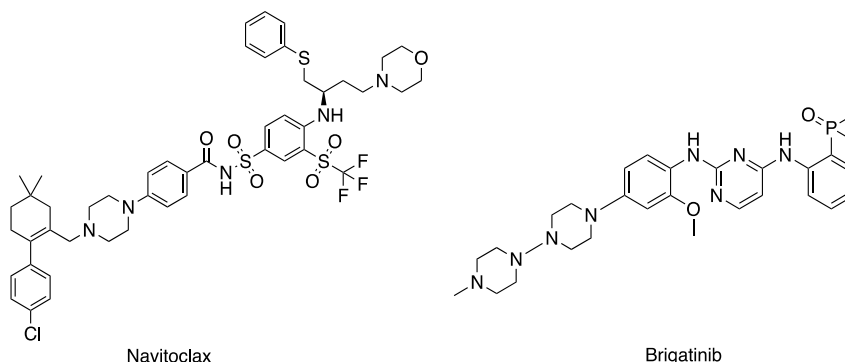


Figure 3 The structural formulae of mentioned compounds, Navitoclax & Brigatinib

For therapies to activation of alternative pathways, our first choice should be multiple treatments. Inhibitors of MEK, ERK, MET, HER2, mTOR, PD-1 and IGF1R are united with 1st-generation EGFR-TKIs and 2nd-generation EGFR-TKIs to deal with non-EGFR-dependent Osimertinib tolerance. Moreover, alternate treatment can be used, which takes advantage of the incidental sensitivity of cancer cells [2, 22, 25, 29].

Despite the curative effects of inhibitors to Osimertinib resistance, genetic technologies like gene editing may also play an important role in treating OSIMERTINIB tolerance. New technologies such as using CRISPR-Cas9 to correct the mutant genes might be a promising approach to help patients with Osimertinib resistance regain the sensitivity. However, more research is required to improve the approach.

5. Conclusion

Osimertinib was firstly invented as a therapeutic approach to NSCLC in the first-line treatment and a specific medicine to patients with first-generation and/or second-generation EGFR-TKIs-resistance. However, when treating NSCLC patients with Osimertinib, some patients exerted toxic effects on heart, kidney, as well as drug-resistance problems. The two main toxic effects of Osimertinib on heart, QT prolongation and congestive heart failure, and their possible mechanisms, are summarized in this review. Moreover, the relationship between the dose of Osimertinib and the induced kidney injuries such as renal failure has been paid close attention. The most common AEs of Osimertinib on NSCLC patients are skin diseases and diarrheal diseases. Aplastic anaemia is also found as a new ADR of Osimertinib, which has already been verified. In terms of drug-resistance, the numerous EGFR-dependent and EGFR-independent mechanisms are overviewed, with their potential treatments. This review aims to give researchers a brief introduction to disadvantages of Osimertinib, guiding the way improving the existing problem of Osimertinib for them and working as a reference for clinical application of Osimertinib. In the future, the genetic technologies, big data, and artificial intelligences may play important roles in studying the mechanisms and solutions of the adverse effects and drug-tolerances of Osimertinib, which may help to find better curative approaches with precise optimizations.

References

- [1] R. Govindan, N. Page, D. Morgensztern, et al., Changing epidemiology of small-cell lung cancer in the united states over the last 30 years: Analysis of the surveillance, epidemiologic, and end results database. *Journal of clinical oncology*, 2006, pp. 4539-4544. DOI: <https://dx.doi.org/10.1200/JCO.2005.04.4859>
- [2] A. Leonetti, S. Sharma, R. Minari, et al., Resistance mechanisms to osimertinib in egfr-mutated non-small cell lung cancer. *British journal of cancer*, 2019, pp. 725-737. DOI: <https://dx.doi.org/10.1038/s41416-019-0573-8>

- [3] X. Liu, X. Chen, L. Shi, et al., The third-generation egfr inhibitor azd9291 overcomes primary resistance by continuously blocking erk signaling in glioblastoma. *Journal of Experimental & Clinical Cancer Research*, 2019, pp. 1-14. DOI: <https://dx.doi.org/10.1186/s13046-019-1235-7>
- [4] H. Ogata, Y. Yamamoto, T. Harada, et al., Severe aplastic anemia during osimertinib therapy in a patient with egfr tyrosine kinase inhibitor-resistant non-small cell lung cancer. *Journal of Thoracic Oncology*, 2017, pp. e46-e47. DOI: <https://dx.doi.org/10.1016/j.jtho.2016.12.023>
- [5] N.S. Young and J. Maciejewski, The pathophysiology of acquired aplastic anemia. *New England journal of medicine*, 1997, pp. 1365-1372. DOI: <https://dx.doi.org/10.1056/NEJM199705083361906>
- [6] L. Sala, M. Mancin, A. Pastore, et al., Aplastic anemia in a patient with advanced lung adenocarcinoma during first line osimertinib: A case report and literature review. *Lung Cancer*, 2020, pp. 120-122. DOI: <https://dx.doi.org/10.1016/j.lungcan.2020.02.019>
- [7] D.W. Kaufman, J.P. Kelly, J.M. Jurgelson, et al., Drugs in the aetiology of agranulocytosis and aplastic anaemia. *European Journal of Haematology*, 1996, pp. 23-30. DOI: <https://dx.doi.org/10.1111/j.1600-0609.1996.tb01641.x>
- [8] J.C. Marsh. Hematopoietic growth factors in the pathogenesis and for the treatment of aplastic anemia. in *Seminars in hematology*. 2000. Elsevier. DOI: [https://doi.org/10.1016/S0037-1963\(00\)90032-5](https://doi.org/10.1016/S0037-1963(00)90032-5)
- [9] M.E. Lacouture, Mechanisms of cutaneous toxicities to egfr inhibitors. *Nature Reviews Cancer*, 2006, pp. 803-812. DOI: <https://doi.org/10.1038/nrc1970>
- [10] M.E. Lacouture, M.J. Anadkat, R.-J. Bensadoun, et al., Clinical practice guidelines for the prevention and treatment of egfr inhibitor-associated dermatologic toxicities. *Supportive Care in Cancer*, 2011, pp. 1079-1095. DOI: <https://dx.doi.org/10.1007/s00520-011-1197-6>
- [11] P.A. Wu, Y. Balagula, M.E. Lacouture, et al., Prophylaxis and treatment of dermatologic adverse events from epidermal growth factor receptor inhibitors. *Current opinion in oncology*, 2011, pp. 343-351. DOI: <https://dx.doi.org/10.1097/CCO.0b013e328347406>
- [12] T. Oyakawa, K. Nakashima, and T. Naito, Cardiac dysfunction caused by osimertinib. *Journal of Thoracic Oncology*, 2017, pp. e159-e160. DOI: <https://dx.doi.org/10.1016/j.jtho.2017.05.016>
- [13] H. Watanabe, E. Ichihara, H. Kano, et al., Congestive heart failure during osimertinib treatment for epidermal growth factor receptor (egfr)-mutant non-small cell lung cancer (nslc). *Internal Medicine*, 2017, pp. 2195-2197. DOI: <https://dx.doi.org/10.2169/internalmedicine.8344-16>
- [14] A. Cuomo, A. Rodolico, A. Galdieri, et al., Heart failure and cancer: Mechanisms of old and new cardiotoxic drugs in cancer patients. *Cardiac failure review*, 2019, pp. 112. DOI: <https://dx.doi.org/10.15420/cfr.2018.32.2>
- [15] T. Niitsu, T. Hayashi, J. Uchida, et al., Drug-induced kidney injury caused by osimertinib: Report of a rare case. *Nephron*, 2022, pp. 58-63. DOI: <https://dx.doi.org/10.1159/000518774>
- [16] L.V. Sequist, J.-Y. Han, M.-J. Ahn, et al., Osimertinib plus savolitinib in patients with egfr mutation-positive, met-amplified, non-small-cell lung cancer after progression on egfr tyrosine kinase inhibitors: Interim results from a multicentre, open-label, phase 1b study. *The Lancet Oncology*, 2020, pp. 373-386. DOI: [https://dx.doi.org/10.1016/S1470-2045\(19\)30785-5](https://dx.doi.org/10.1016/S1470-2045(19)30785-5)
- [17] A. Crosnier, C. Abbara, M. Cellier, et al., Renal safety profile of egfr targeted therapies: A study from vigibase® the who global database of individual case safety reports. *Cancers*, 2021, pp. 5907. DOI: <https://dx.doi.org/10.3390/cancers13235907>
- [18] Y.Z. Van Sebille, R.J. Gibson, H.R. Wardill, et al., Erbb small molecule tyrosine kinase inhibitor (tki) induced diarrhoea: Chloride secretion as a mechanistic hypothesis. *Cancer treatment reviews*, 2015, pp. 646-652. DOI: <https://dx.doi.org/10.1016/j.ctrv.2015.05.011>
- [19] H.S. Rugo, J.A. Di Palma, D. Tripathy, et al., The characterization, management, and future considerations for erbb-family tki-associated diarrhea. *Breast cancer research and treatment*, 2019, pp. 5-15. DOI: <https://dx.doi.org/10.1007/s10549-018-05102-x>
- [20] Y. Kim, A. Quach, S. Das, et al., Potentiation of calcium-activated chloride secretion and barrier dysfunction may underlie egf receptor tyrosine kinase inhibitor-induced diarrhea. *Physiological reports*, 2020, pp. e14490. DOI: <https://doi.org/10.14814/phy2.14490>

- [21] C. Stirling, J. Houston, S. Robertson, et al., Diarrhoea, vomiting and ace inhibitors:—an important cause of acute renal failure. *Journal of human hypertension*, 2003, pp. 419-423. DOI: <https://dx.doi.org/10.1038/sj.jhh.1001571>
- [22] Q. PEI and J. SUN, Research progress of osimertinib acquired resistance. *Chinese Journal of Clinical Pharmacology and Therapeutics*, 2021, pp. 105. DOI: <https://dx.doi.org/10.12092/j.issn.1009-2501.2021.01.014>
- [23] J. Fassunke, F. Müller, M. Keul, et al., Overcoming egfr724s-mediated osimertinib resistance through unique binding characteristics of second-generation egfr inhibitors. *Nature communications*, 2018, pp. 1-13. DOI: <https://dx.doi.org/10.1038/s41467-018-07078-0>
- [24] Y. Kobayashi, T. Fujino, M. Nishino, et al., Egfr t790m and c797s mutations as mechanisms of acquired resistance to dacomitinib. *Journal of Thoracic Oncology*, 2018, pp. 727-731. DOI: <https://dx.doi.org/10.1016/j.jtho.2018.01.009>
- [25] D. Hayakawa, F. Takahashi, Y. Mitsuishi, et al., Activation of insulin-like growth factor-1 receptor confers acquired resistance to osimertinib in non-small cell lung cancer with egfr t790m mutation. *Thoracic cancer*, 2020, pp. 140-149. DOI: <https://dx.doi.org/10.1111/1759-7714.13255>
- [26] Y. Mu, X. Hao, P. Xing, et al., Acquired resistance to osimertinib in patients with non-small-cell lung cancer: Mechanisms and clinical outcomes. *Journal of cancer research and clinical oncology*, 2020, pp. 2427-2433. DOI: <https://dx.doi.org/10.1007/s00432-020-03239-1>
- [27] K. Uchibori, N. Inase, M. Araki, et al., Brigatinib combined with anti-egfr antibody overcomes osimertinib resistance in egfr-mutated non-small-cell lung cancer. *Nature communications*, 2017, pp. 1-16. DOI: <https://dx.doi.org/10.1038/ncomms14768>
- [28] X. Wang, L. Zhou, J.C. Yin, et al., Lung adenocarcinoma harboring egfr 19del/c797s/t790m triple mutations responds to brigatinib and anti-egfr antibody combination therapy. *Journal of Thoracic Oncology*, 2019, pp. e85-e88. DOI: <https://dx.doi.org/10.1016/j.jtho.2019.01.015>
- [29] Z.-H. Tang, X.-M. Jiang, X. Guo, et al., Characterization of osimertinib (azd9291)-resistant non-small cell lung cancer nci-h1975/osir cell line. *Oncotarget*, 2016, pp. 81598. DOI: <https://dx.doi.org/10.18632/oncotarget.13150>